Mechanisms of Transmission and Disease in Congenital Viral Infections:

Lessons from Rubella and CMV

Maternal –Fetal Transmission

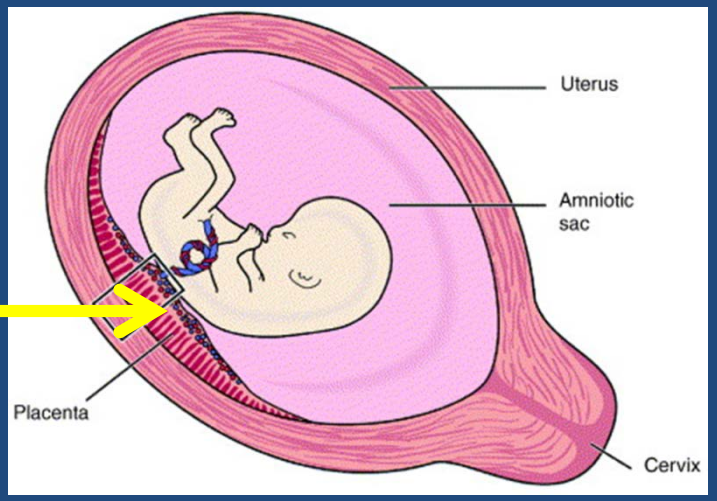

Congenital Infection



Perinatal Infection

Etiologies of Congenital and Perinatal Infections

Congenital Infections
(intrauterine infection)

Cytomegalovirus (10/1000)
Toxoplasma (2/10,000)
Rubella (0)
Syphilis (4.7/1000)
Parvovirus (?)
LCMV (?)
HIV
Zika virus
HSV, HBV, VZV,EBV

Perinatal Infections
(peripartum infections)

HIV
HBV
HCV
HSV, VZV, CMV
Dengue, Chikungunya
Yellow Fever
Zika virus

Birth Rate Brazil 2.9 million/yr
Congenital CMV- 29,000
Congenital Toxoplasmosis-600
Syphilis-9,000

Congenital Infection: Transplacental Transmission

3 dynamic, complex biological systems determine outcome

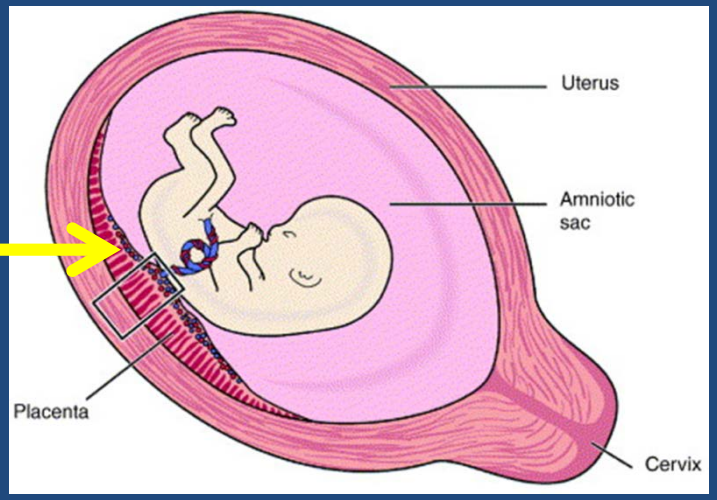

Control of virus infection during pregnancy: Importance of Maternal Immunity

Rubella Virus/Congenital Rubella Syndrome (CRS)

Maternal primary infection → viremia → placental infection → **fetal infection**

Adaptive immunity blocks/modulates this step in transmission to fetus

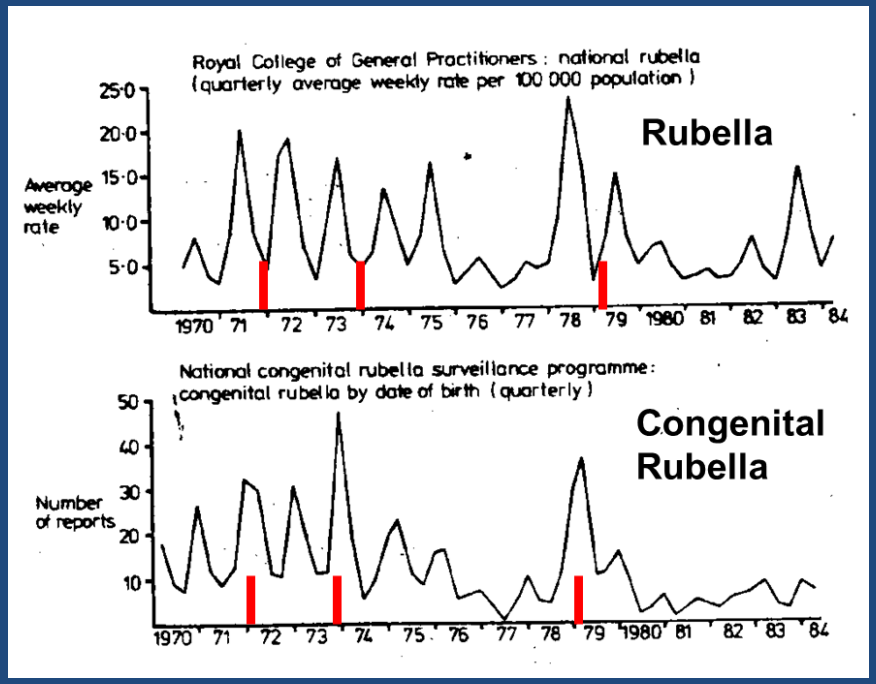

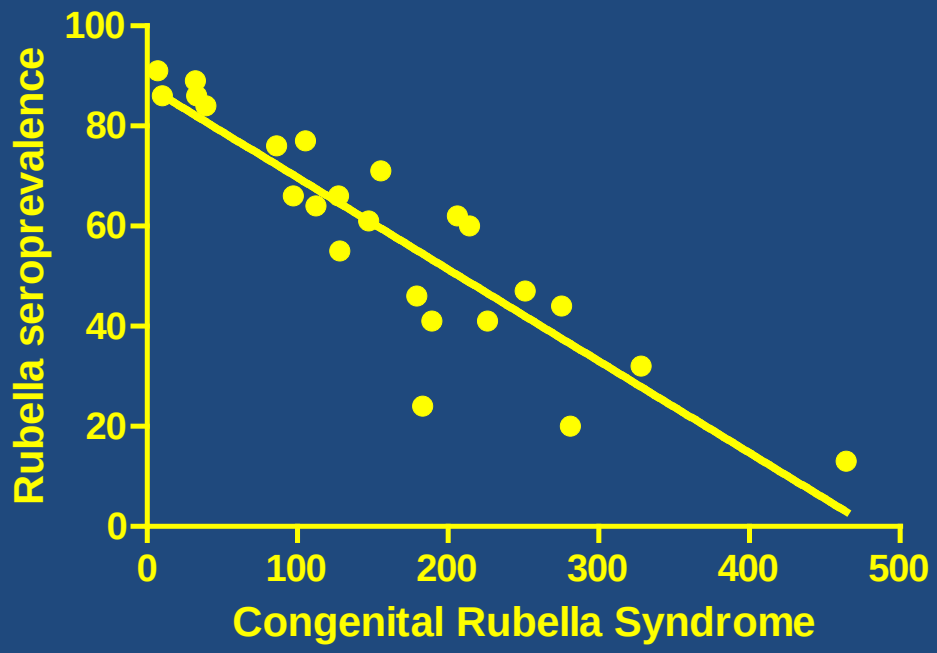

Modified from Cutts F., Int Journal of Epidemiology 1999

Control of virus infection during pregnancy: Undefined Importance of Maternal Immunity

Cytomegalovirus (CMV); Congenital CMV infection

Maternal primary/non-primary infection → viremia → placental infection → **fetal infection**

↑ ? ↑ ? ↑ ?

Adaptive immunity blocks/modulates these steps in transmission

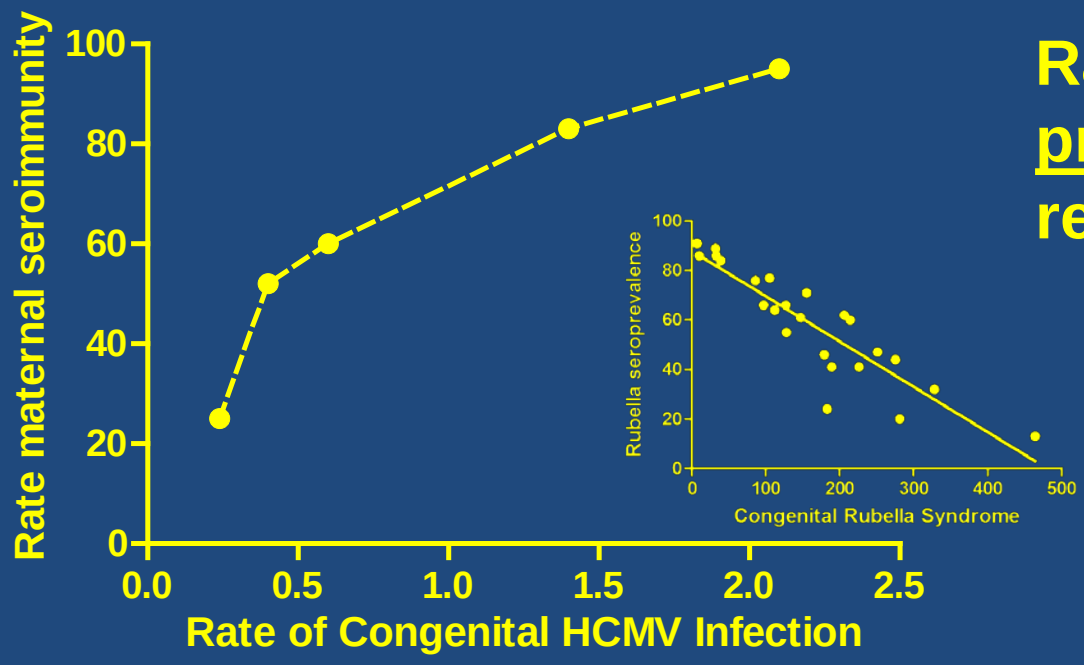

Ratio of non-primary to primary maternal infections resulting in congenital CMV

1) **4.3 low income**
   Stagno, 1982

2) **3.4 overall**
   Wang, 2011

CMV Superinfections

Women with established immunity to CMV can be reinfected with new strains of CMV during pregnancy

A

```
        15                      34
        |                       |
...TVYLLSHLPSQRYGADAAEEALDPHAFHLLLNTYGRPIRFLRENTT...   AD169
.....C.....L.S....E.I..P..*K.......................   Towne
```

B

Maternal Serologic Reactivity				Acquisition of New Antibody Specificity	Sequence Homology	Predicted Amino Acid Sequences of the Amino-Terminal Region of Glycoprotein H from CMV Isolates from Seven Infected Infants
BEFORE PREGNANCY		AT DELIVERY				
AP86	TO86	AP86	TO86			15 34
Negative	Positive	Positive	Positive	Yes	AP86	YLLSHLPSQRYGADAAEEALDPHAFHLLLNTYGRPIRFLRENTT
Positive	Negative	Positive	Positive	Yes	TO86	CLLSHLLSSRYGAEAIEEPLD*KAFHLLLNTYGRPIRFLRENTT
Negative	Positive	Positive	Positive	Yes	AP86	YLLSHLPSQRYGADAAEEALDPHAFHLLLNTYGRPIRFLRENTT
Negative	Negative	Positive	Negative	Yes	AP86	YLLSHLPSQRYGADAAEEALDPHAFHLLLNTYGRPIRFLRENTT
Positive	Positive	Positive	Positive	No	TO86	CLLSHLLSSRYGAEAIEEPLD*KAFHLLLNTYGRPIRFLRENTT
Negative	Positive	Negative	Positive	No	TO86	CLLSHLLSSRYGAEAIEEPLD*KAFHLLLNTYGRPIRFLRENTT
Positive	Negative	Positive	Negative	No	AP86	YLLSHLPSQRYGADAAEEALDPHAFHLLLNTYGRPIRFLRENTT

Boppana, 2001

Table 2: Intrahost Diversity of HCMV Populations in Clinical Samples: Genome Wide Averages

Sample	Variants[1]	π^2 (%)	Mean Diversity (%)	π_{AA}[3] (%)	π_{SYN}[3] (%)	Variable AA Sites[4] (%)
U01	8,562	0.18	0.17	0.14	0.04	12.3
U04	13,335	0.25	0.22	0.15	0.05	13.8
U33	10,318	0.22	0.21	0.16	0.06	14.0

1. Variants are the total intrahost single nucleotide variants.
2. π is the average pairwise distance of sequences in the population.
3. π_{AA} is the intrahost amino acid diversity and π_{SYN} is the diversity of all synonymous mutations.
4. Variable AA Sites are the percentage of amino acid positions in which nonsynonymous intrahost variants were detected.

CMV circulates as *"quasi species"*

Deep sequencing of CMV patient isolates reveals complex mixtures of genetically diverse viruses

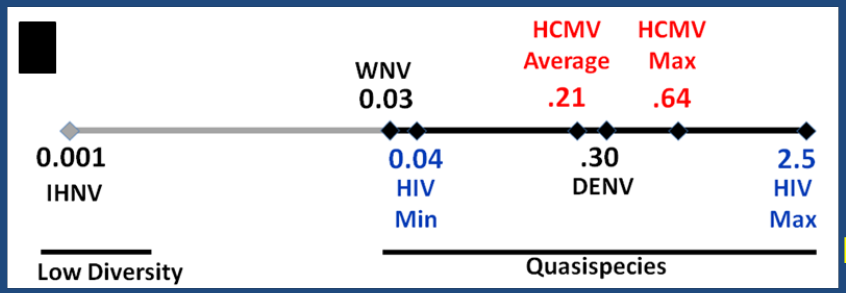

Kowalik, 2010, Renzette, 2015)

Infection at Maternal-Fetal Interface: The Placenta

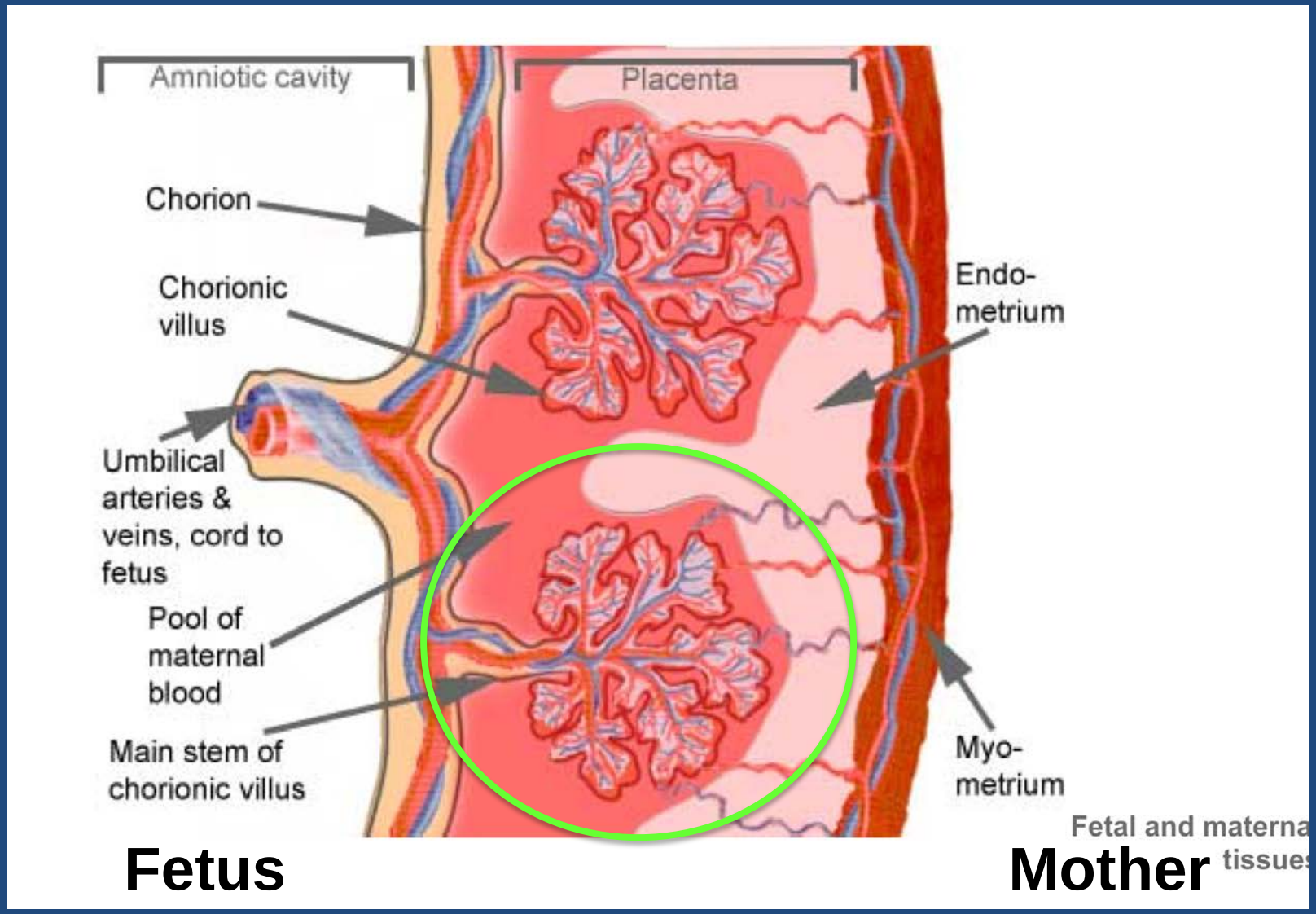

Infection at Maternal-Fetal Interface: Transmission of Virus to the Fetus

Features of placental development that could facilitate intrauterine transmission.

Developmental feature	Gestational age	Postulated Mechanism
placental Blood Flow	mid-2nd trimester	increased blood flow with increased likelihood of placental exposure to virus in blood
thinning of placental (villous)membraned	mid-2nd trimester (CMV > 2nd)	maternal blood and fetal capillary endothelium separated only by syncytiotrophoblasts
increased villous vascularization	early-3rd trimester	increased surface area of villous
cells in villous stroma (endothelial,fibroblasts, Hofbauer)	1st-3rd trimester (Rubella 1st>3rd)	permissive cells for virus replication and amplification

Virus Infection of the Placenta: Disease Secondary to Placental Dysfunction

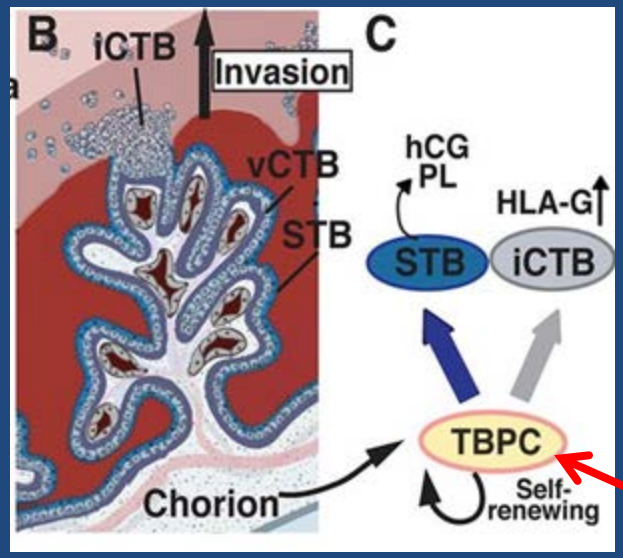

Tabata, et.al. JVirol,2015

Virus infection of Trophoblast Progenitor Cells (TBPC) of placenta can limit placental development and function.

HCMV

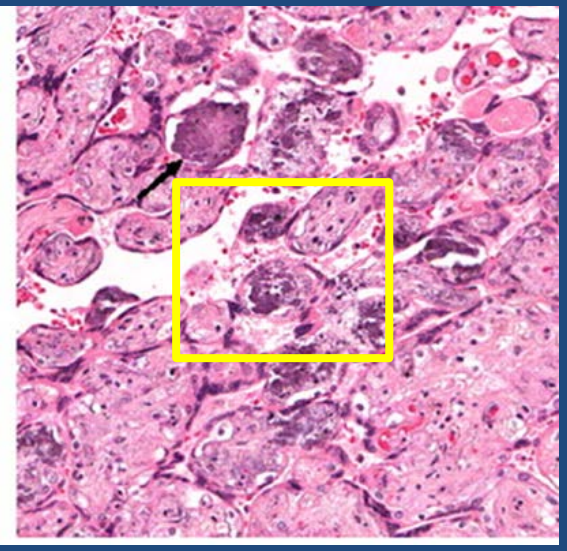

Iwasenko, J, et.al., JInfecDis,2011

Virus infection of the placenta can lead to a fetal thrombotic vasculopathy and loss of placental function.

HCMV associated placental lesions have been linked to stillbirths and IGUR

Disease: CNS Findings Associated with Congenital Viral Infections

Clinical Findings

1) Microcephaly
2) Neurological deficits, seizures
3) Deficits in perception (sight and hearing)
4) Neurodevelopmental delays

Laboratory/Imaging Findings

1) Structural malformations of brain (developmental stage specific)
2) Calcifications/ vascular damage
3) Loss of neuronal mass
4) Evidence of CNS inflammation

Zika Virus Associated Microcepahly And Computerized Tomographic (CT) Findings.

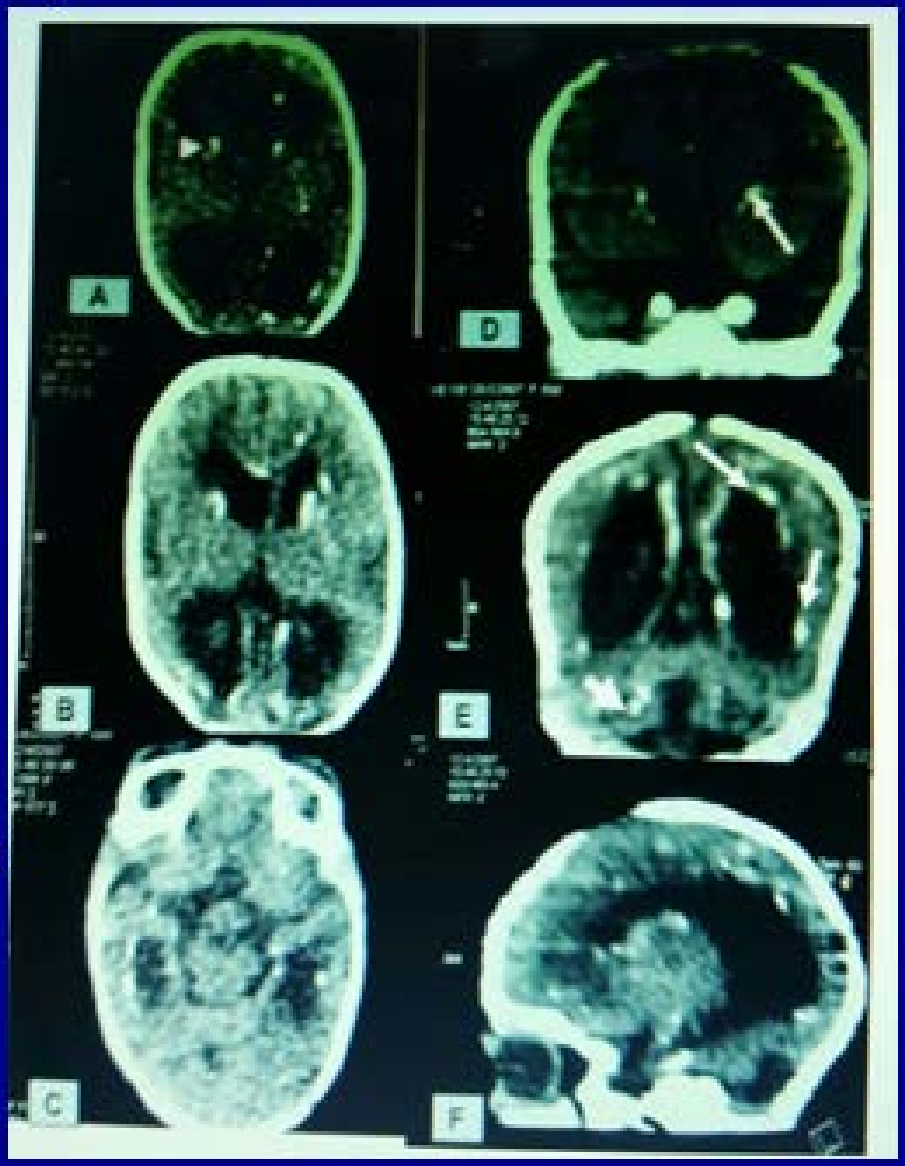

Photograph and radiograph provided by:
Amilcar Tanuri , Prof Titular -UFRJ
Laboratório de Virologia Molecular
Instituto de Biologia –
Departamento de Genética
Universidade Federal do Rio de Janeiro
(UFRJ)

Microcephaly and computerized tomographic findings of infant with congenital cytomegalovirus infection

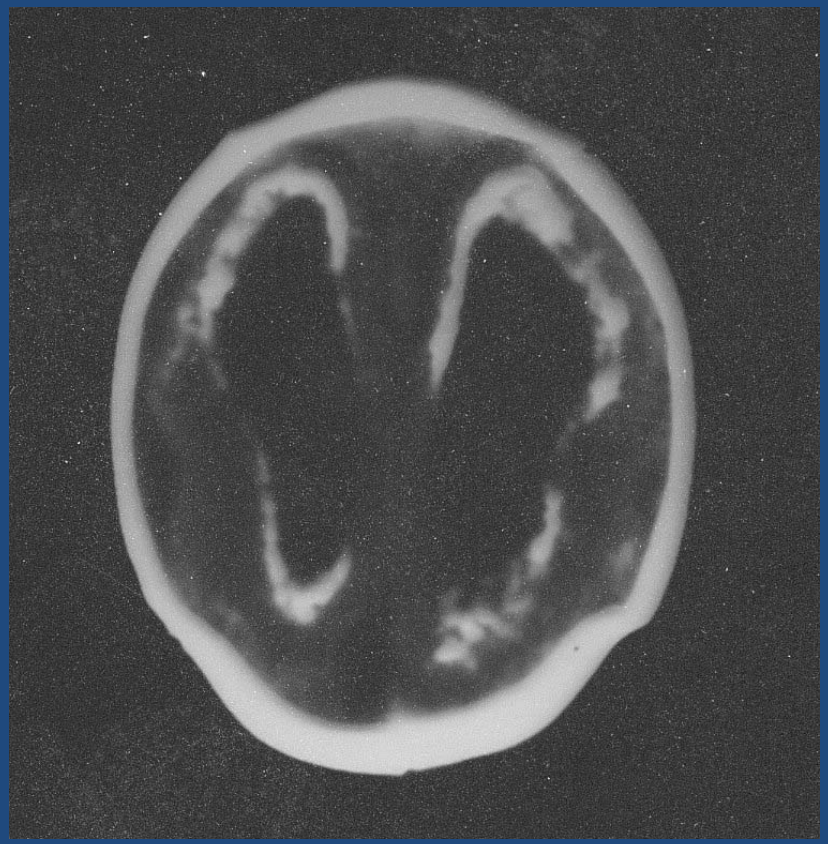

Structural Damage to Developing CNS following Intrauterine CMV Infection

Number of cases	Source	Findings (also reported for Zika)	Reference
9	Autopsy	encephalitis (55%); cerebellar dysplasia (11%); micropolygyria (11%); calcifications (33%)	Becroft, 1982
6	Autopsy	encephalitis(100%);cerebellar dysplasia(66%);microgyria, calcifications	Marques-Dias, 1984
15	Autopsy	encephalitis(80%); migration deficits(50%); cerebellar dysplasia(40%)	Perlman, 1992
31	Autopsy	encephalitis (55%);white matter involvement(13%)	Gabrielli, 2009
8	Autopsy	encephalitis(12%);calcifications(72%)	Benoist, 2008
5	Imaging	lissencephaly, pachygyria(5); calcifications	Hayward, 1991
11	Imaging	lissencephaly(36%); cerebellar hypoplasia(64%);polymicrogyra (45%); calcifications (100%)	Barkovich, 1994
11	Imaging	cerebellar hypoplasia (55%);polymicrogyria (45%)	De Vries, 2006
56	Imaging	calcifications (77%)	Boppana, 1996
6	Imaging	cerebellar hypoplasia (33%); pachygyria(66%)	Sugita, 1991
49	Imaging	39% abonormal imaging; migration abnormalities(2%);calcifications(10%); cerebellar abnormalities (2%)	Benoist, 2008
38	Imaging	24% ventriculomegaly;calcifications (5%);cerebellar dysplasia(8%);cortical abnormality (13%); microcephaly (18%)	Doneda,2010

Mechanisms of CNS Damage Associated with Congenital Viral Infections

Direct virus-mediated damage to the developing CNS

1) Loss of neural progenitor cells (early gestation infection>damage)
2) Loss of supporting vasculature in the CNS
3) Altered cellular positioning/connectivity-increased apoptosis
4) Virus-induced alterations neurotransmitter responses

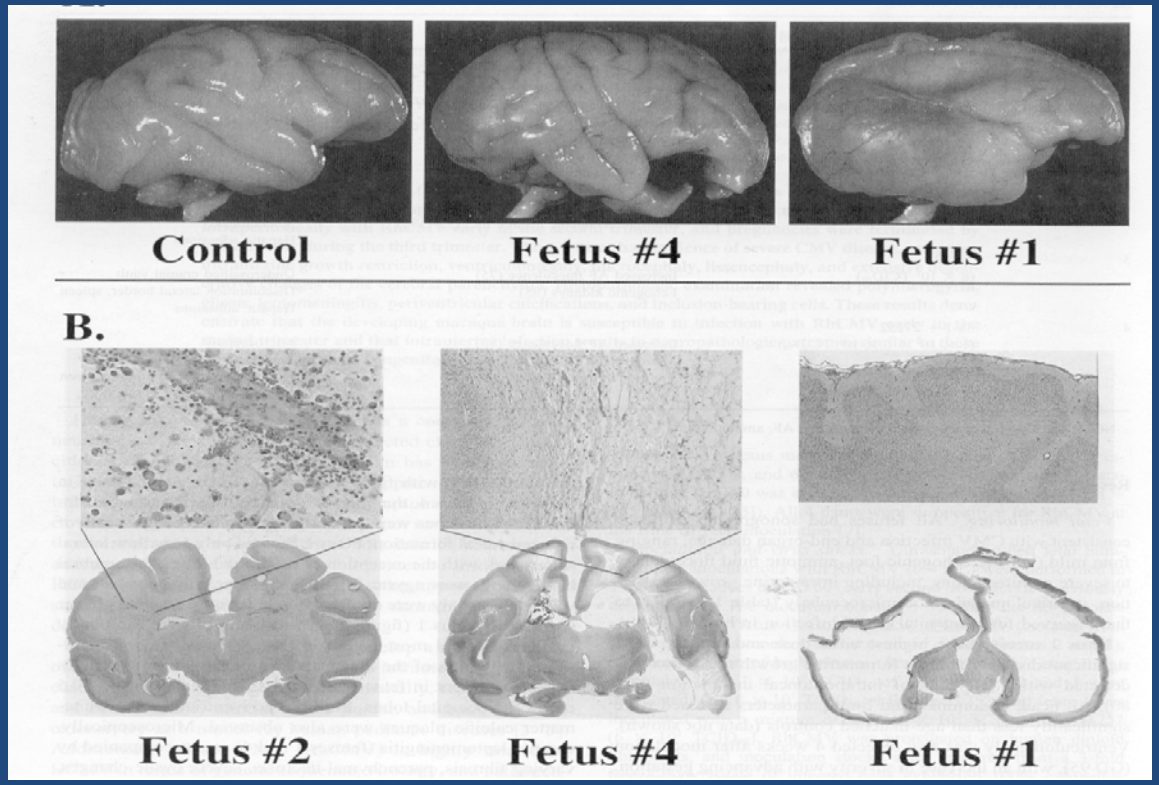

Phenotypic variation in brain pathology following intrauterine infection with Rhesus CMV (#4 vs #1)

Tarantal, et.al., J Infec Dis, 1998

Proliferation of neuron progenitors in ventricular epithelium slows during cortical neurogenesis

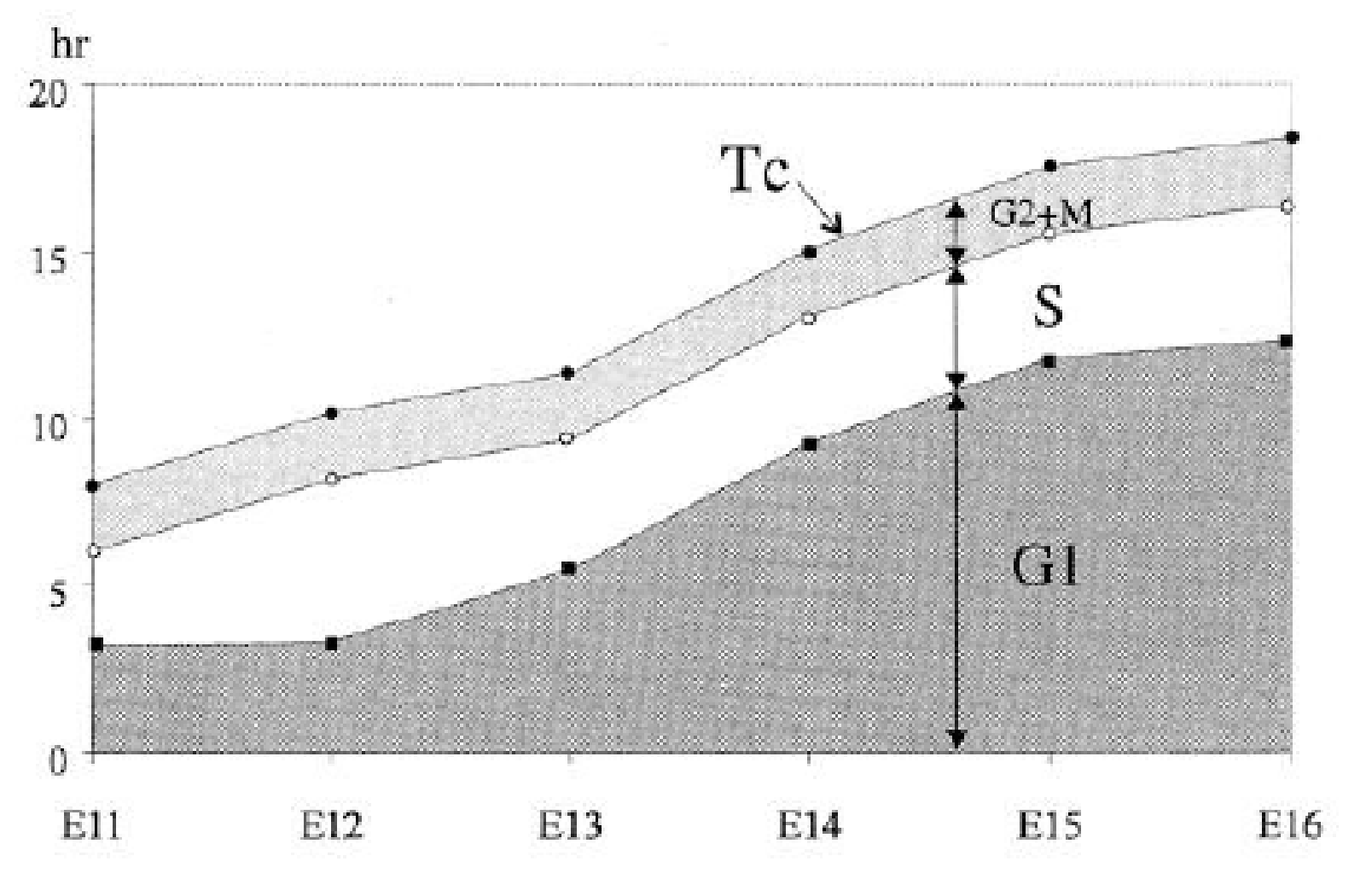

Takahashi, JNeurosci, 1995

Cerebellar growth in the human fetus

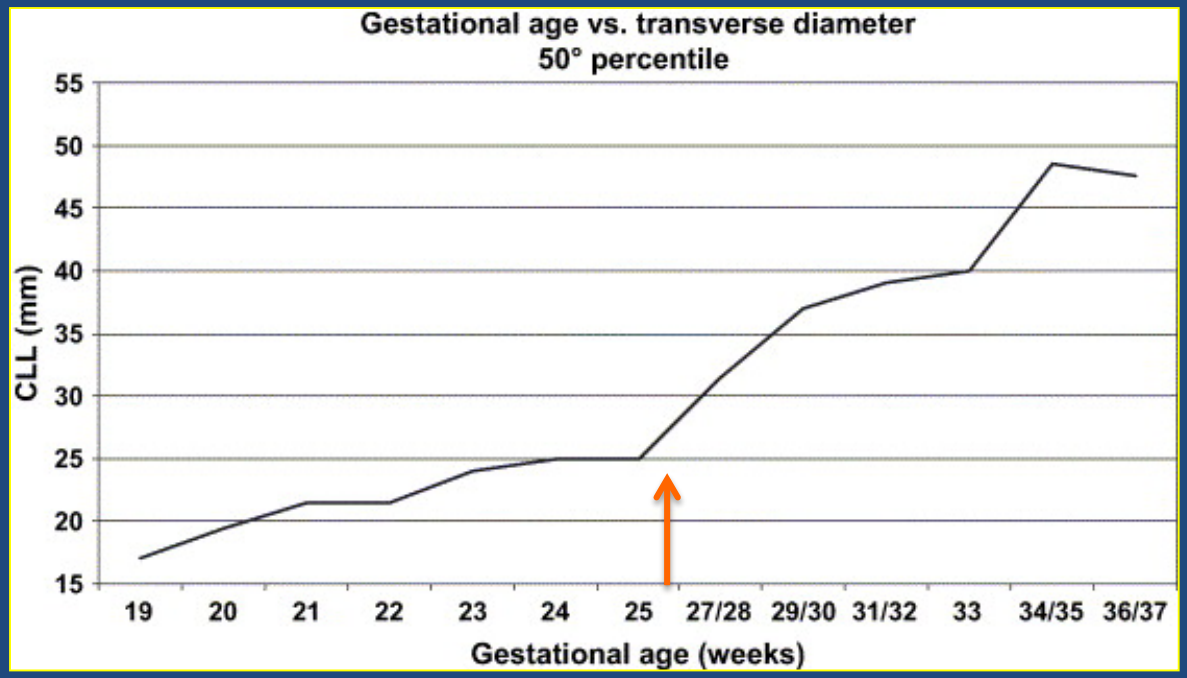

Triulizi, F., Seminars in Fetal and Neonatal Medicine, 2005

Cerebellar growth in the mouse

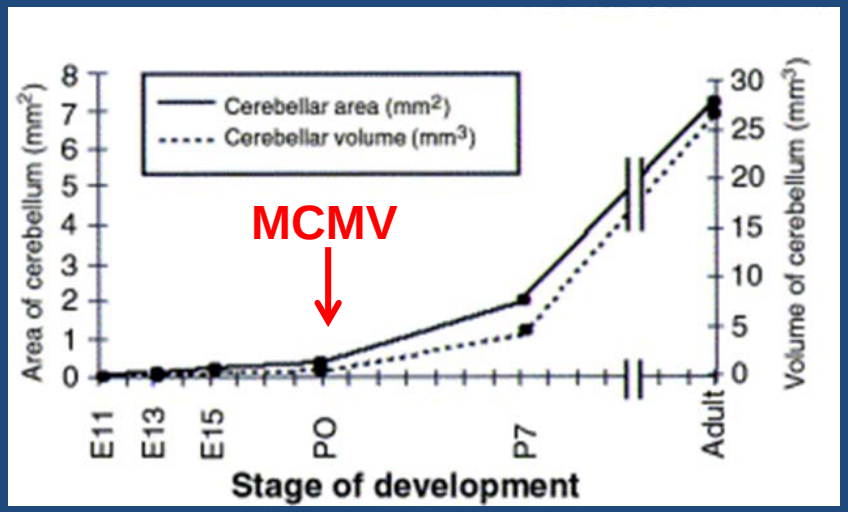

Goldowitz, Trends Neurosci, 1998

Mechanisms of CNS Damage Associated with Congenital Viral Infections

Indirect virus-induced damage to the CNS: Immunopathology

Focal Encephalitis

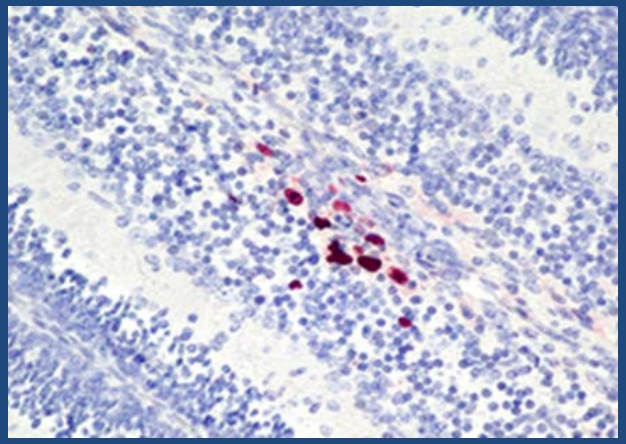

Cerebellar hypoplasia following MCMV infection of newborn mouse

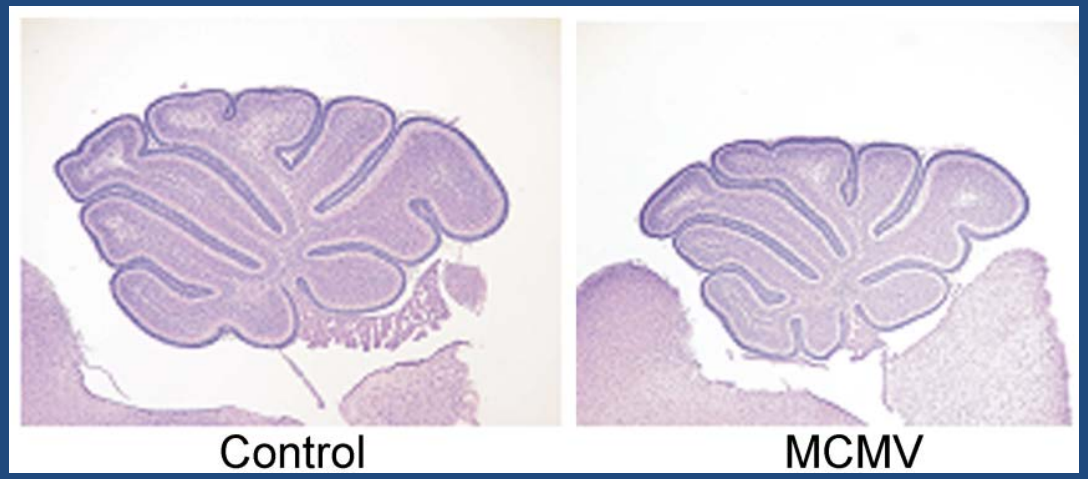



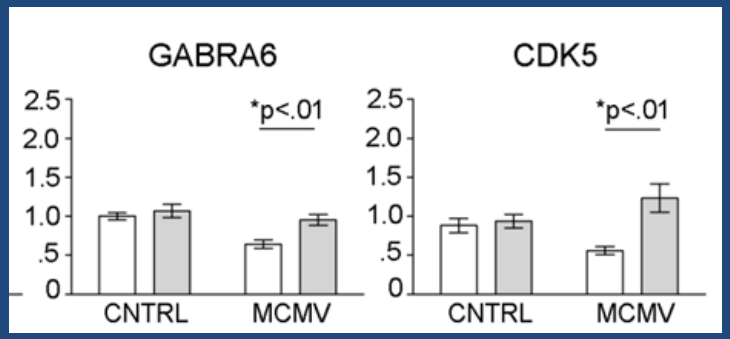

Intrauterine CMV or Zika virus Infection: Shared Mechanisms of CNS Damage

Infections early in CNS development:

Severe, symmetrical structural damage

1) ***Loss of neural progenitor cells***
2) ***Alterations in proliferative capacity of neural progenitor cells***
3) ***Loss of supporting vasculature***

Infection later in CNS development:

Mild to minimal structural damage

1) ***Impact on different regions of brain, i.e. hindbrain, auditory pathways***
2) ***Loss of cellular positioning and cellular connectivity***

Mechanisms that could result in these clinical findings:

1) Direct viral effects on neuroprogenitors

2) Indirect effects (inflammation; damage to vasculature; placental dysfunction)

Research Priorities:

1) Generate comprehensive and definitive natural history studies of congenital and perinatal Zika virus infections (will require improved diagnostics, prospective studies, newborn screening, comprehensive long term follow-up)

2) Develop informative animal model systems that recapitulate key aspects of human infections